

Crangon crangon Bacilliform virus (CcBV) in brown shrimp (*Crangon crangon*) and *Pandalus montagui* Bacilliform virus (PmBV) in pink shrimp (*Pandalus montagui*) from the Wash fishery, North Sea



Brown shrimp (*Crangon crangon*)

Crangon crangon Bacilliform Virus (CcBV) infection of hepatopancreatocytes of brown shrimp, *Crangon crangon*

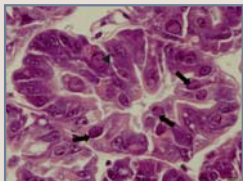


Figure 1: Tubule within the hepatopancreas displaying hypertrophic and eosinophilic nuclei (arrows). Margination of the chromatin and compartmentalisation of karyoplasm (arrowhead) can be seen. H&E stain. Scale bar = 100µm

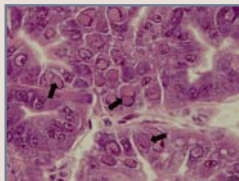


Figure 2: Hypertrophic eosinophilic nuclei with marginalized chromatin (arrows). H&E stain. Scale bar = 100µm

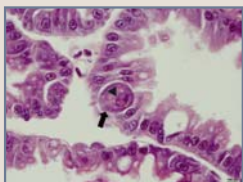


Figure 3: Infected cell showing separation from neighbouring uninfected cells (arrow). Nuclear compartmentalisation can also be seen (arrowhead). H&E stain. Scale bar = 100µm

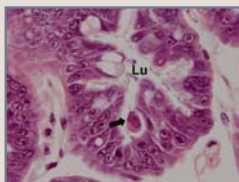


Figure 4: Infected cell (arrow) sloughed into lumen (Lu) of tubule; remaining cells appear uninfected. H&E stain. Scale bar = 100µm

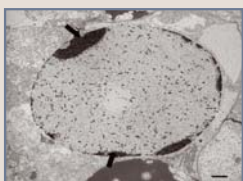


Figure 5: Hypertrophic nuclei with marginalized chromatin (arrows); CcBV virions are present throughout the nucleus in transverse and longitudinal section. TEM. Scale bar = 1µm

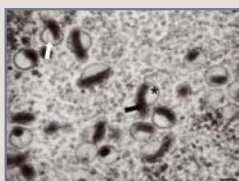


Figure 6: Longitudinal and transverse section through CcBV virions. Virions consist of an electron dense core (black arrow) surrounded by a trilaminar membrane with a lateral extension (asterisk) at one end. Tail like appendage can be seen within the expansion (white arrow). TEM. Scale bar = 100nm

- Histopathological screening of brown shrimp (*Crangon crangon*) and pink shrimp (*Pandalus montagui*) from the Wash fishery, North Sea revealed the presence of two separate viruses infecting the hepatopancreas.
- Crangon crangon* Bacilliform Virus (CcBV) has been previously described infecting brown shrimp from several UK estuaries (Stentiford *et al.*, 2004)
- A new virus, distinct from CcBV was observed infecting *Pandalus montagui* from this fishery. The virus is named *Pandalus montagui* Bacilliform Virus (PmBV) (Hicks *et al.*, 2007)
- Ultrastructural and pathological observations of CcBV and PmBV suggest that both viruses possess affinities to other intranuclear bacilliform viruses (or non-occluded baculoviruses) of Crustacea.
- CcBV and PmBV infect epithelial cells; cells contain eosinophilic, hypertrophied nuclei with marginal chromatin.
- The prevalence and severity of infection of PmBV in pink shrimp appeared to be less than that seen for CcBV infection of brown shrimp from the same site. Previous observations suggest CcBV infection prevalence of up to 100% in estuarine *C. crangon* (Stentiford *et al.*, 2004).
- Ultrastructural observation of PmBV revealed rod-shaped virions with a distinctive kink in the middle of the nucleocapsid. Kinked-nucleocapsids were bound by a simple trilaminar envelope. PmBV virions did not appear to form arrays and were not encapsulated within occlusion bodies but did appear to be partially occluded in an amorphous matrix that corresponded to a granular viroplasm.
- PmBV differed from the previously described CcBV in that CcBV virions instead consisted of a straight, rod-like nucleocapsid enclosed within a simple trilaminar envelope with a distinct protrusion at one end.
- Anecdotal evidence suggests cyclical population shifts between *C. crangon* dominance and *P. montagui* dominance in the Wash fishery.
- Both shrimps support important fisheries in Europe and further work is now required to investigate whether viral infections such as CcBV and PmBV have the potential to regulate population structure within these fisheries.

References

- Stentiford, G.D., Bateman, K., Feist, S.W. (2004) Pathology and ultrastructure of an intranuclear bacilliform virus (IBV) infecting brown shrimp *Crangon crangon* (Decapoda: Crangonidae). *Diseases of Aquatic Organisms* 58, 89-97.
- Hicks, R.J., Bateman, K.S., Stentiford, G.D. (2007). *Pandalus montagui* Bacilliform Virus (PmBV) in pink shrimp (*Pandalus montagui*) from the Wash, United Kingdom. *Diseases of Aquatic Organisms*. (in preparation)



Pink shrimp (*Pandalus montagui*)

Pandalus montagui Bacilliform Virus (PmBV) infection of hepatopancreatocytes of pink shrimp, *Pandalus montagui*

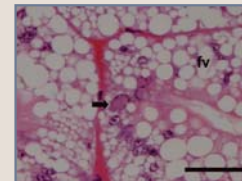


Figure 7: Light infections were depicted by small clusters of infected cells (arrow). R-cells contained abundant fat vacuoles (FV) and tubules were closely aligned with neighbouring tubules. H&E stain. Scale bar = 100µm

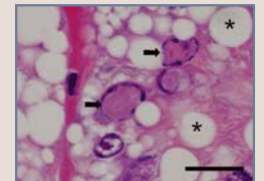


Figure 8: Hypertrophic and eosinophilic nuclei with marginalized chromatin (arrow) with R-cells. Fat vacuoles (asterisk). H&E stain. Scale bar = 25µm

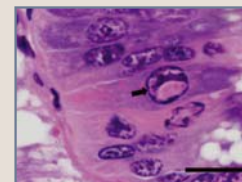


Figure 9: Infected F-cell with hypertrophic nucleus (arrow). H&E stain. Scale bar = 25µm

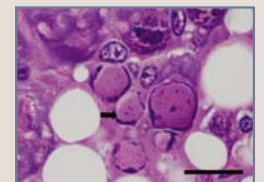


Figure 10: Cluster of nuclei within adjacent R-cells (arrow). H&E stain. Scale bar = 25µm




Figure 11: Hypertrophic nuclei with marginalised chromatin (black arrow) containing PmBV virions. Virions are present in transverse and longitudinal section; virions appear to cluster at the nuclear membrane (white arrow). TEM. Scale bar = 2µm

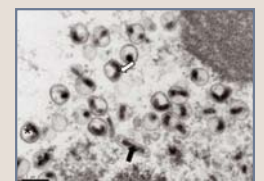


Figure 12: Longitudinal and transverse section through PmBV virions. Virions consist of an electron dense core (black arrow) surrounded by a trilaminar membrane with a lateral extension (asterisk) at one end. PmBV virions display a distinctive kink (white arrow) in the middle of the nucleocapsids. TEM. Scale bar = 0.2µm