

Description of a *Hematodinium* sp. infecting the chinese swimming crab *Portunus trituberculatus*

Introduction

Members of the genus *Hematodinium* are parasitic dinoflagellates that infect a number of crustacean genera, many of which are exploited in commercial fisheries. Currently there are only two described species of *Hematodinium*; however there are numerous reports of *Hematodinium*-like species infecting other crustaceans.

In autumn 2005 and 2006, mortalities of the cultured swimming crab, *Portunus trituberculatus*, were observed from commercial crab ponds in the Zhejiang Province of China. During this time the infection prevalence approached 90%. Samples were collected from infected crabs and preserved for histological, molecular and ultrastructural studies to assist in identification of a pathogen that could be responsible for the mass mortalities. We report the discovery of the etiological agent, a *Hematodinium* sp. infecting *P. trituberculatus*, and describe the associated pathology, ultrastructure, and taxonomic position of this *Hematodinium* species.



Figure 1 A-B: *Portunus trituberculatus* culture ponds in the Zhoushan Islands (Zhejiang Province), and associated crab mortalities.

Materials and methods

Crab tissue samples were prepared for wax histology by standard methods, 5µm sections were cut and stained with Haematoxylin & Eosin (H&E) and observed by light microscopy. Haemolymph samples were prepared for electron microscopy by prefixing in 2.5% glutaraldehyde in 0.2M PBS and post fixed with OsO₄. Sections were stained and observed using a JEOL JEM-1210 Electron Microscope.

DNA was extracted from infected *P. trituberculatus* haemolymph samples, and the first internal transcribed spacer (ITS1) of the ribosomal RNA (rRNA) gene complex was amplified using generic *Hematodinium* primers (Hudson & Adlard, 1994). Positive amplicons for each sample were cloned, and multiple DNA clones (at least 3) from each positive sample were sequenced on a 3130 Prism genetic analyzer (Applied Biosystems). The ITS1 regions were aligned with other *Hematodinium* spp. sequences in GenBank (Small *et al.*, 2007) using the CLUSTAL-W algorithm in the MacVector 8.2 sequence analysis package (Accelrys). Parsimony analysis was performed using PAUP 4.0b10 software.

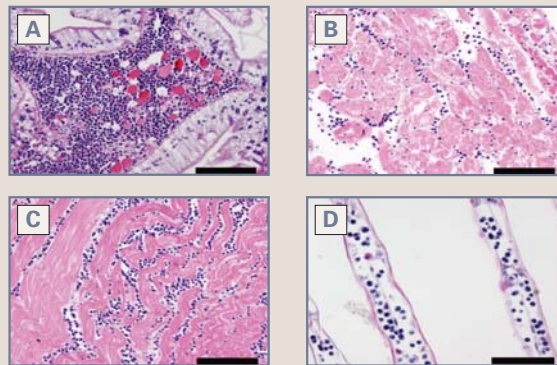


Figure 2 A-D: A. Hepatopancreas showing infiltration of *Hematodinium* sp. parasites (H) into the hemal space (Hs). B. Heart showing infiltration of *Hematodinium* sp. parasites (H) into spaces between myocardial muscle tissues (M). C. Muscle tissue showing separation of muscle bundles by infiltration of *Hematodinium*. D. Gill showing *Hematodinium* sp. parasites (H) and granular host hemocytes (arrows) within the vascular space. H & E, bar = 100µm.

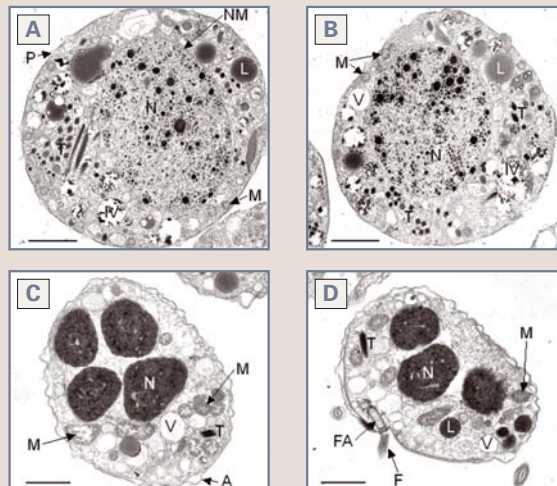


Figure 3 A & B: Vegetative dinoflagellates showing the nucleus (N) with a "speckled" appearance of condensed chromatin, vacuoles (V), mitochondria (M), inclusion vesicle (IV), lipid globules (L), pellicle (P), nuclear membrane (NM), and trichocysts (T). Scale bar = 2µm. C & D. Dinospores showing swollen alveoli (A), condensed chromatin in the nucleus (N), mitochondria (M), vesicles (V), trichocysts (T), flagellum (F), and flagellar attachment site (FA). Scale bar = 1µm.

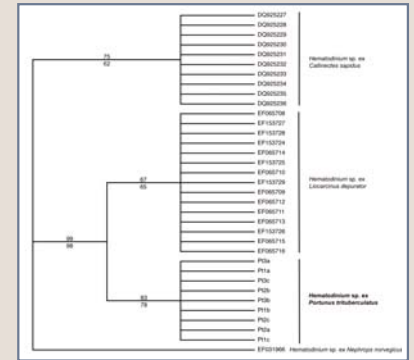


Figure 4: Strict bootstrap consensus tree resulting from parsimony analysis conducted with rRNA ITS1 region sequences from the *Hematodinium* sp. infecting *P. trituberculatus* and other *Hematodinium* spp. Parsimony and jackknife support values for each clade are given above and below the lines, respectively. The *Hematodinium* sp. from *P. trituberculatus* is indicated in bold.

Results and discussion

This is the first report of a *Hematodinium* sp. from Asia, and is also the first species found infecting a host under aquaculture conditions. The pathology was typical of other *Hematodinium* sp. infections of decapods, with replacement of haemocytes by large numbers of uni- and multinucleate parasite stages in all tissues examined. Ultrastructurally, vegetative parasite stages displayed a "speckled" appearance of condensed chromatin, trichocysts, lipid droplets and inclusion vesicles. Dinospores displayed a condensed chromatin, trichocysts, alveolar membrane, and a flagellar attachment site. Molecular characterisation of the ITS1 rRNA region of the parasite revealed a close similarity with the *Hematodinium* spp. infecting harbour crabs (*Liocarcinus depurator*) from the English coastline, and blue crabs (*Callinectes sapidus*) from Virginia, USA. However, the ITS1 region sequences from the *Hematodinium* species infecting *P. trituberculatus* was found to be distinct from these, suggesting the presence of a new species of *Hematodinium* in Asia. Future studies are planned to investigate the seasonality of infection in *P. trituberculatus*, and identify other *Hematodinium* spp. infections in Asian crustacean hosts.

Acknowledgements

We wish to thank Patrice Mason and Kersten for providing EM and histological support.

References

- Hudson, D.A. & Adlard, R.D. (1994). PCR-techniques applied to *Hematodinium* spp. and *Hematodinium*-like dinoflagellates in decapod crustaceans. *Diseases of Aquatic Organisms* 20, 203-206.
- Small, H.J., Shields, J.D., Hudson, K.L., Reece, K.S. (2007) Molecular detection of the *Hematodinium* sp. infecting the blue crab, *Callinectes sapidus*. *Journal of Shellfish Research* 26: 131-139.