

A NON-OCCLUDED, INTRANUCLEAR BACILLIFORM VIRUS (IBV) INFECTING THE BROWN SHRIMP *Crangon crangon* (DECAPODA: CRANGONIDAE)

by Grant Stentiford, Kelly Bateman and Stephen Feist

Introduction

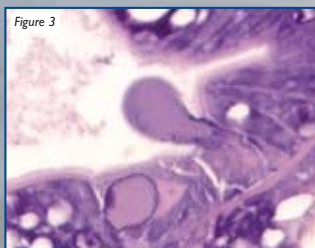
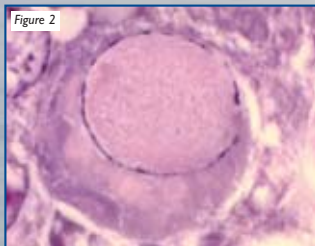
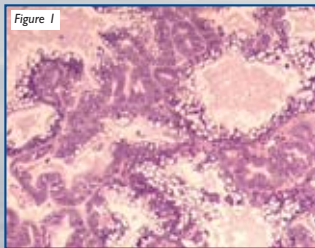
- A highly prevalent non-occluded intranuclear bacilliform virus (IBV) has been discovered in brown shrimp (*Crangon crangon*) from UK estuaries.
- Shrimp were captured during the screening of crustaceans and molluscs for the biological effects of contaminants as part of the National Marine Monitoring Programme (NMMP).
- This is the first report of an IBV in the Crangonidae family.

Pathology

- Infects the epithelial cells of the hepatopancreas, causing necrosis (Figure 1) in up to 98 % of brown shrimp from UK estuaries (Figure 4).
- Virus-infected epithelial cells contained eosinophilic hypertrophied nuclei with marginalised chromatin (Figure 2). The basement membrane was often separated from neighbouring cells and nuclei often appeared apoptotic.
- In heavily-infected shrimp, apoptotic cells were expelled into the lumen of the hepatopancreatic tubules and the tubules became degenerate (Figure 3).

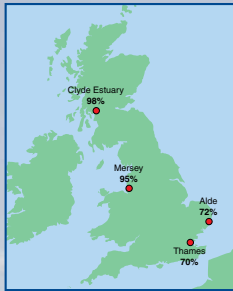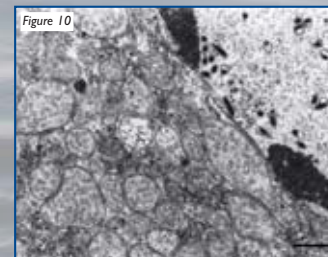
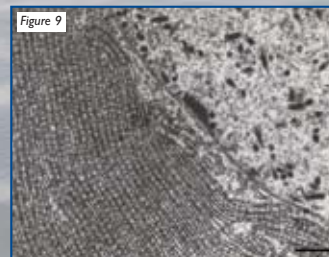
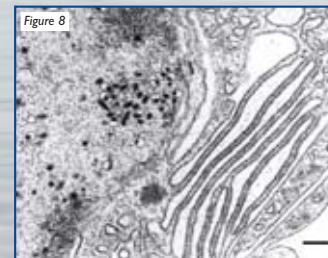
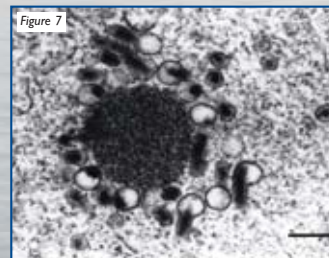
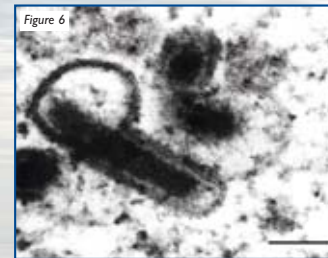
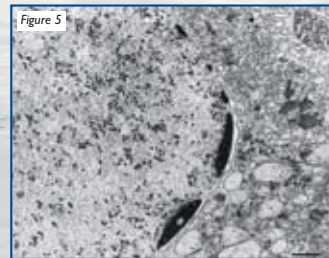


Figure 4: *C. crangon* were sampled from estuarine sites in England and Scotland. The highest prevalence of IBV-infected shrimps was seen in the Clyde estuary



The Virus

- Transmission electron microscopy of hypertrophic nuclei revealed large numbers of rod-shaped envelope bound virions (Figure 5). Virions possessed a trilaminar envelope expanded at one end (Figure 6).
- Virions did not form arrays and were not encapsulated within occlusion bodies but did appear present in a granular viroplasm (Figure 7).
- Massive proliferation of endoplasmic reticulum and mitochondria was observed in infected cells (Figures 8, 9 and 10).
- Ultrastructure, morphology and size of the complete virion associates them closely with IBVs previously reported from other decapod crustaceans.



Individual and population health status

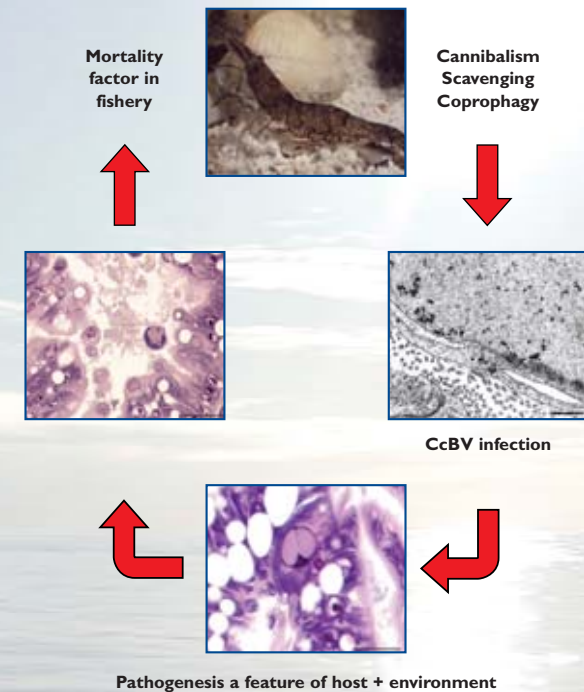


Figure 11: IBV cycling in *C. crangon* populations. Prevailing environmental conditions may affect prevalence and pathogenicity

Significance

- *C. Crangon* is a ubiquitous species found in European estuaries and coastal waters.
- It supports an important fishery in Europe, with over 25,000 t captured per annum (estimated value of over 80M Euro in 2000).
- Pathological manifestation of IBV infection in this species could act as a population modulator and may be exacerbated by stressful conditions caused by pollution and fishing (Figure 11).
- Further studies comparing this IBV to similar commercially significant viruses of decapods is required.

Acknowledgement

The authors acknowledge the support of the Department for Environment, Food and Rural Affairs (Defra), Water Directorate, Contract No C1617.